



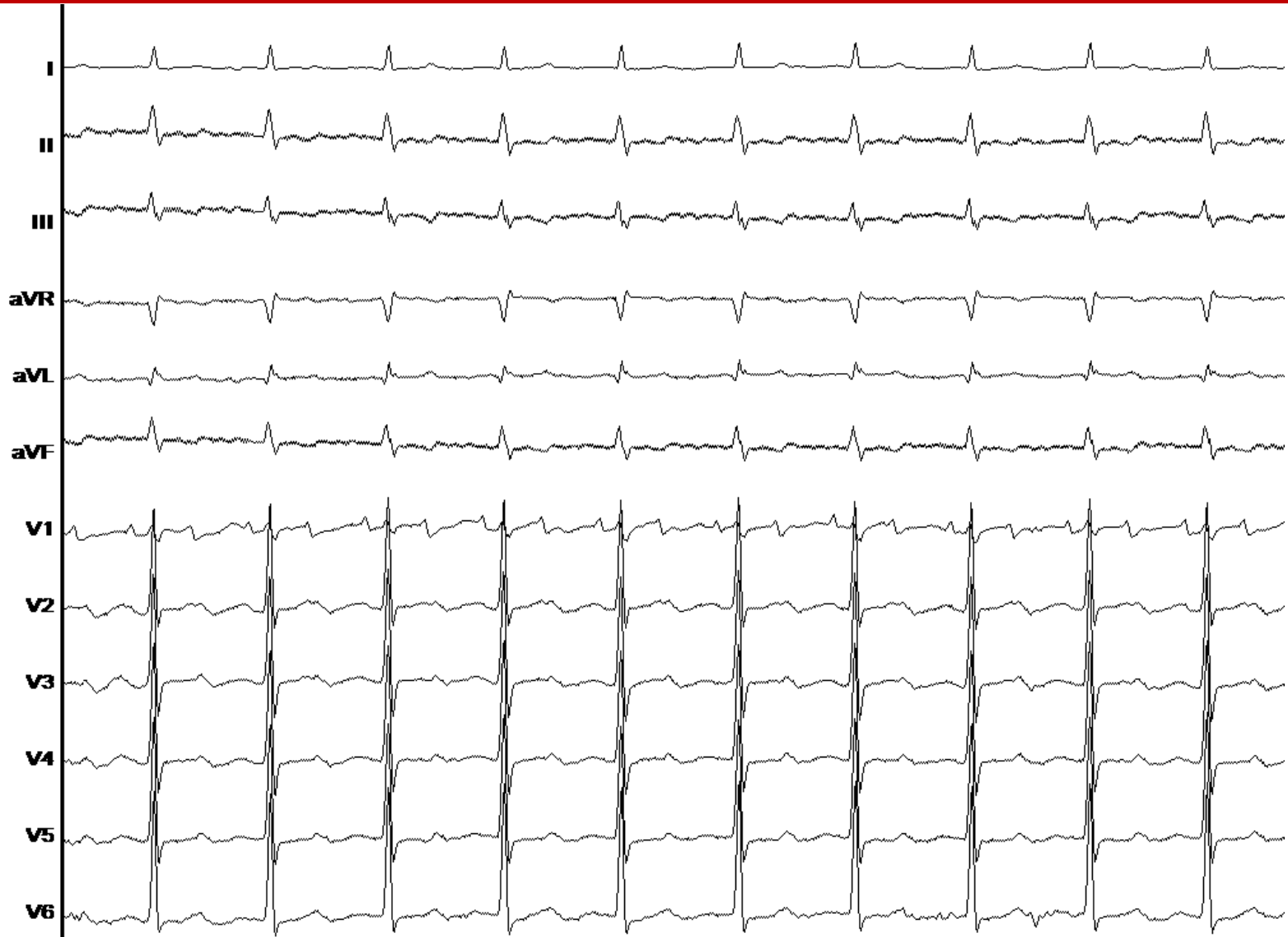
ASSOCIATION DE RYTHMOLOGIE
INTERVENTIONNELLE & STIMULATION

3 flutters en 1

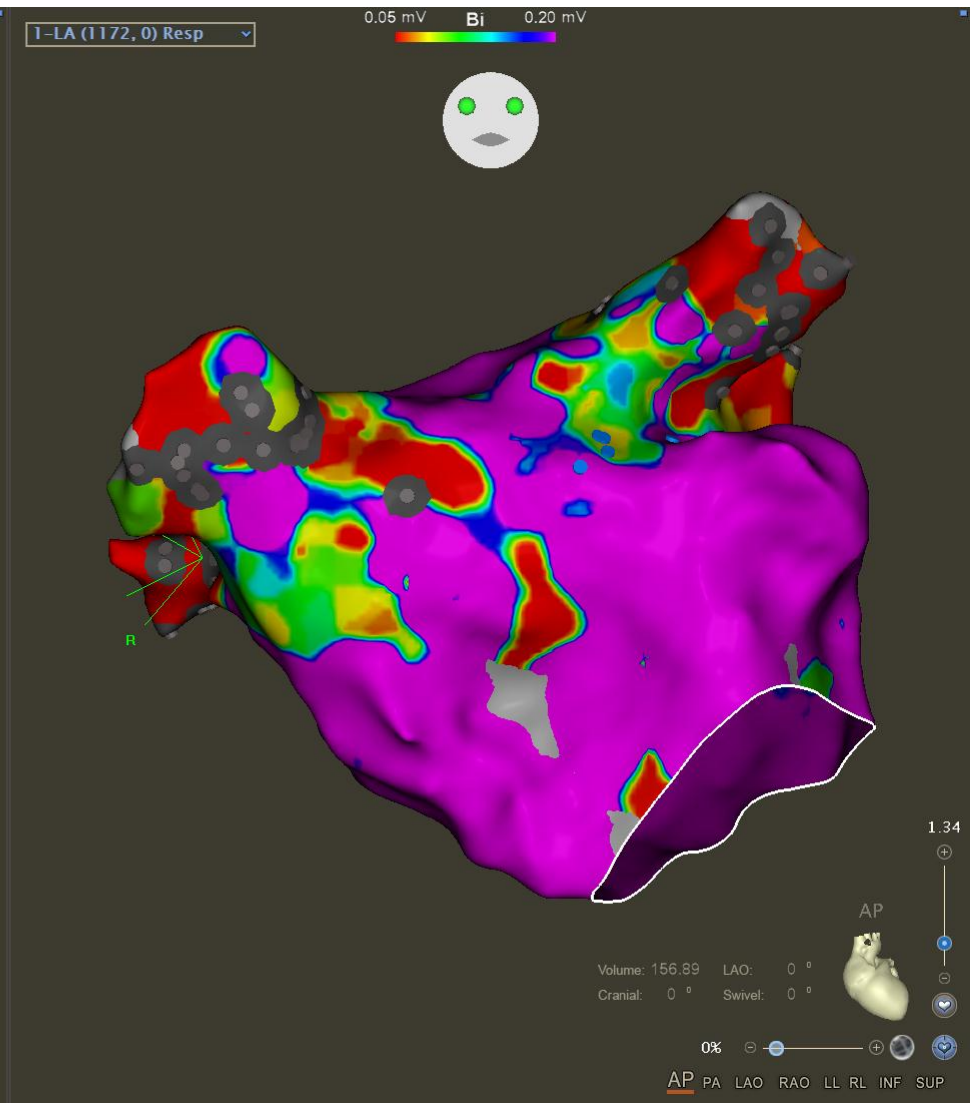
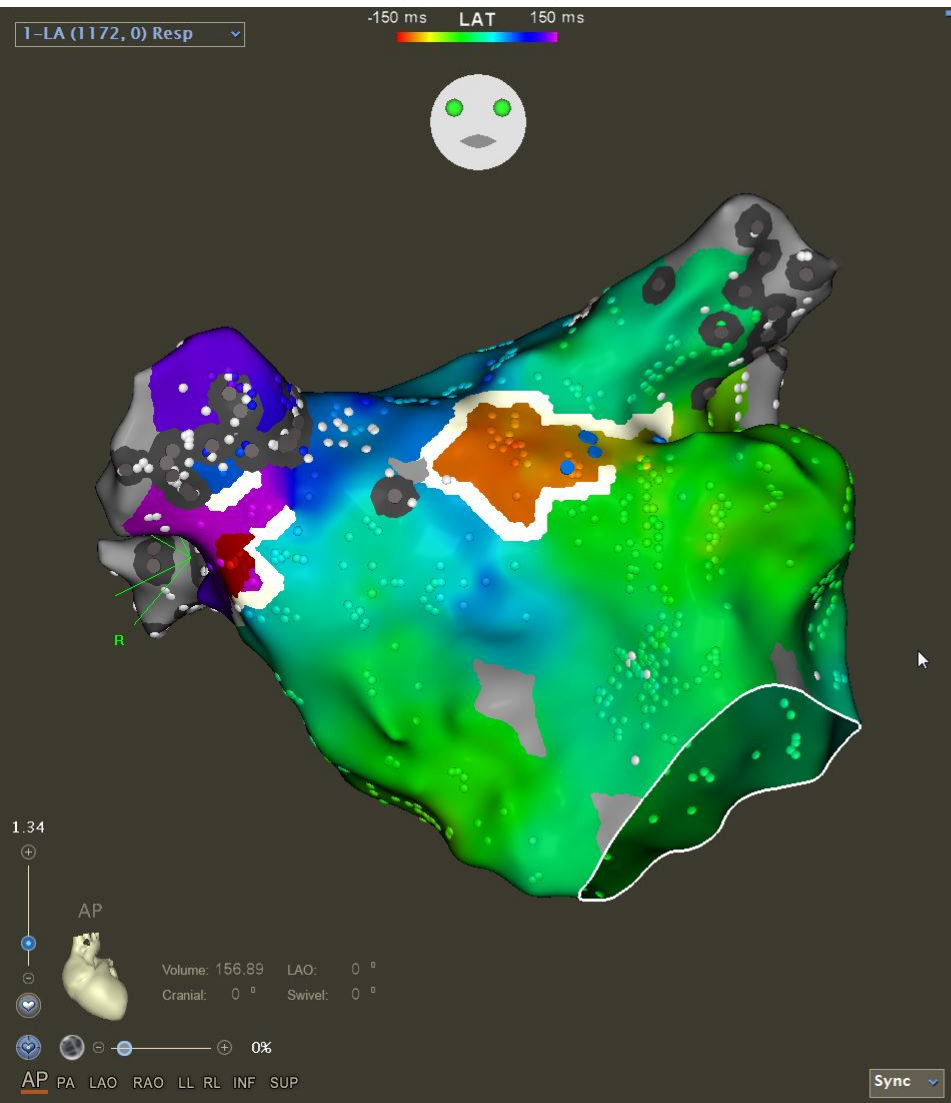
Dr Durand & Dr Rosier

Novembre 2019 - Infirmerie Protestante

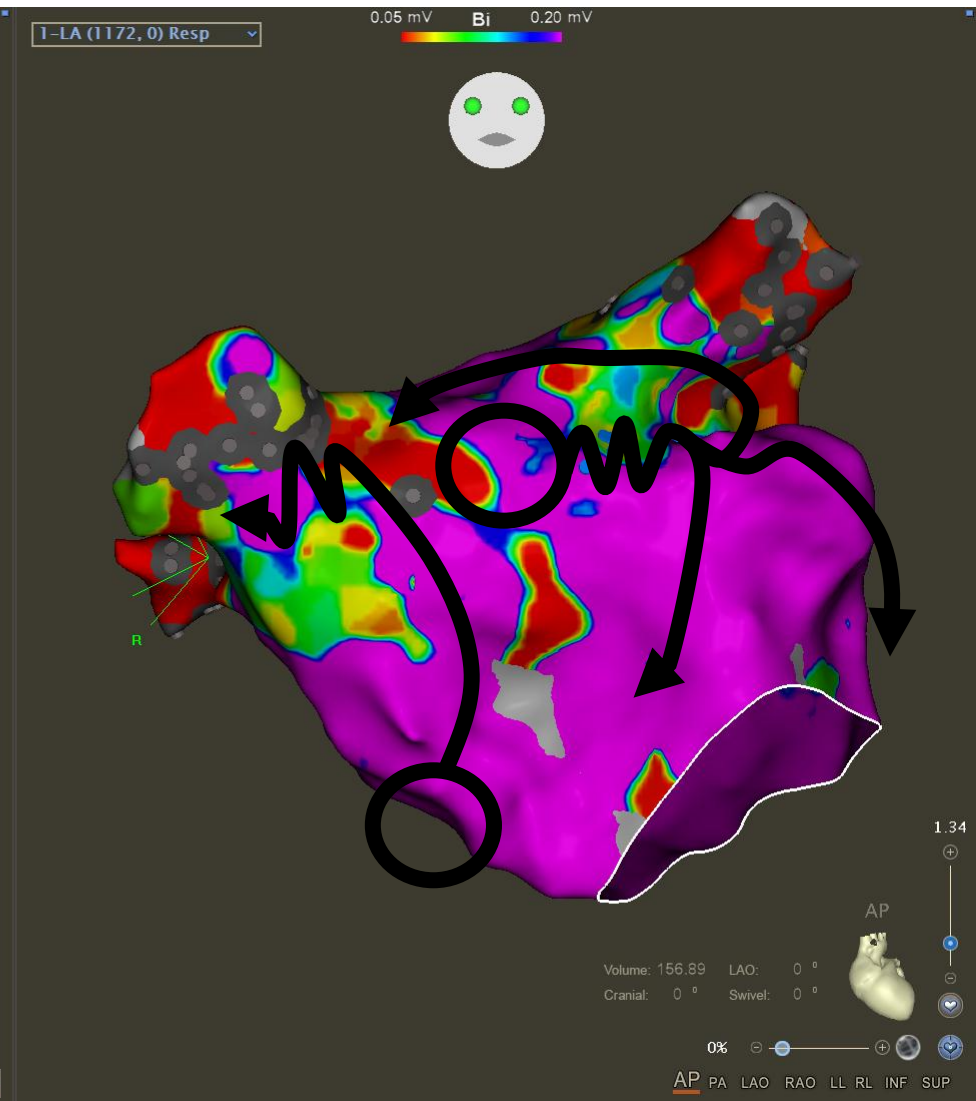
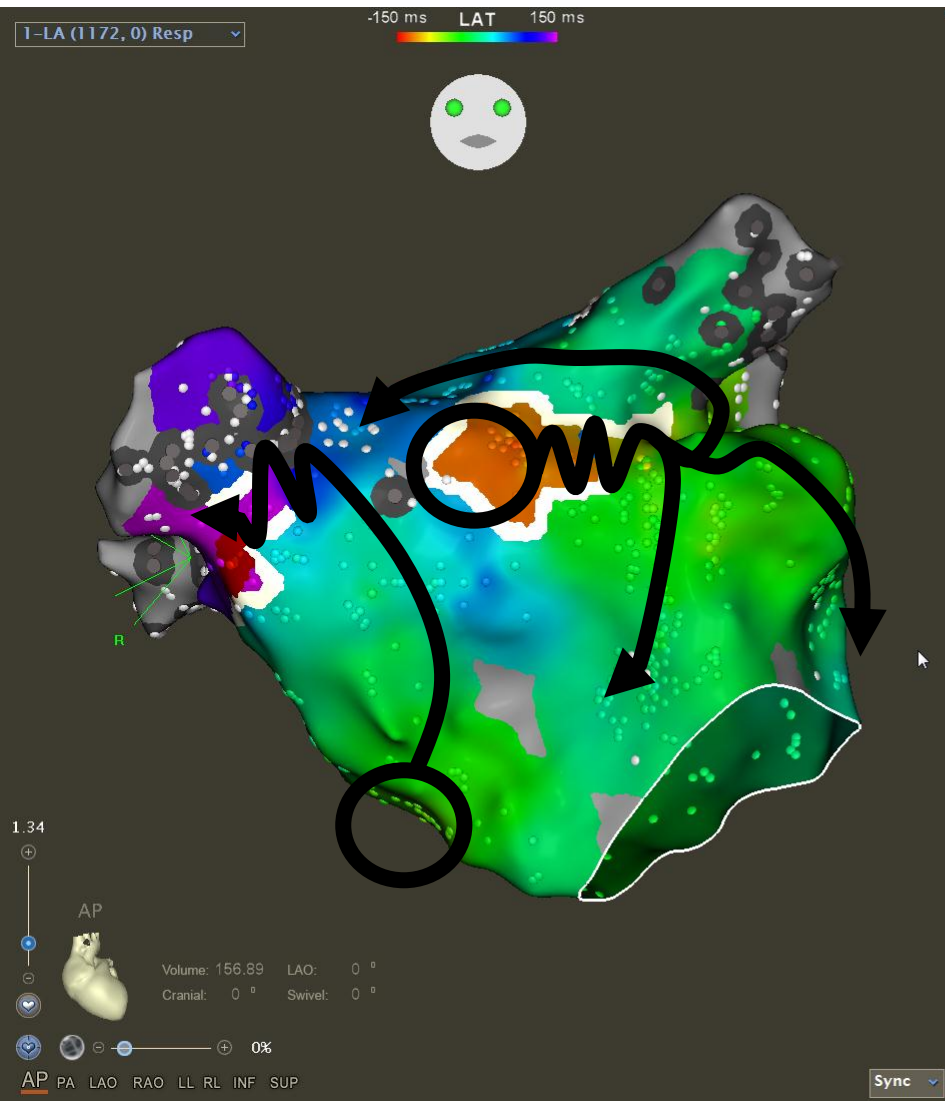
ECG de départ



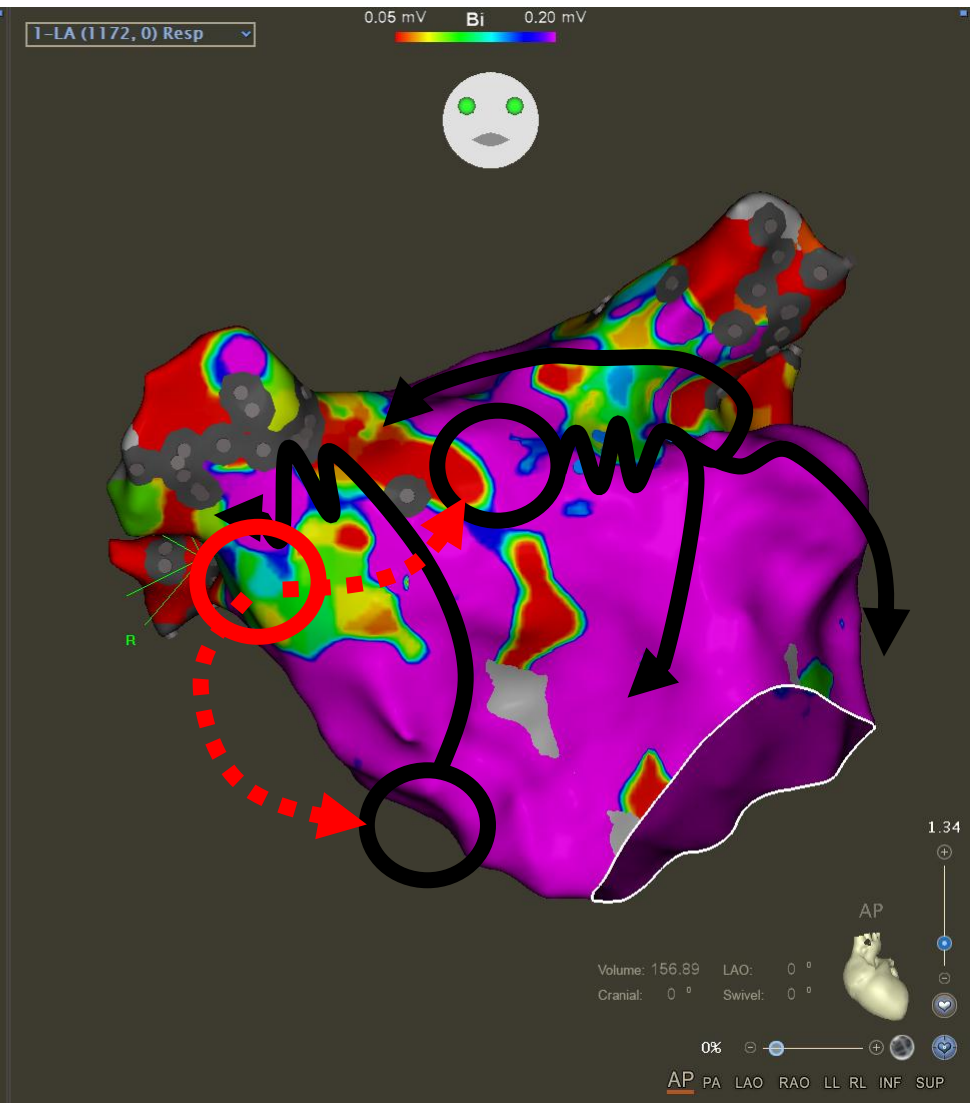
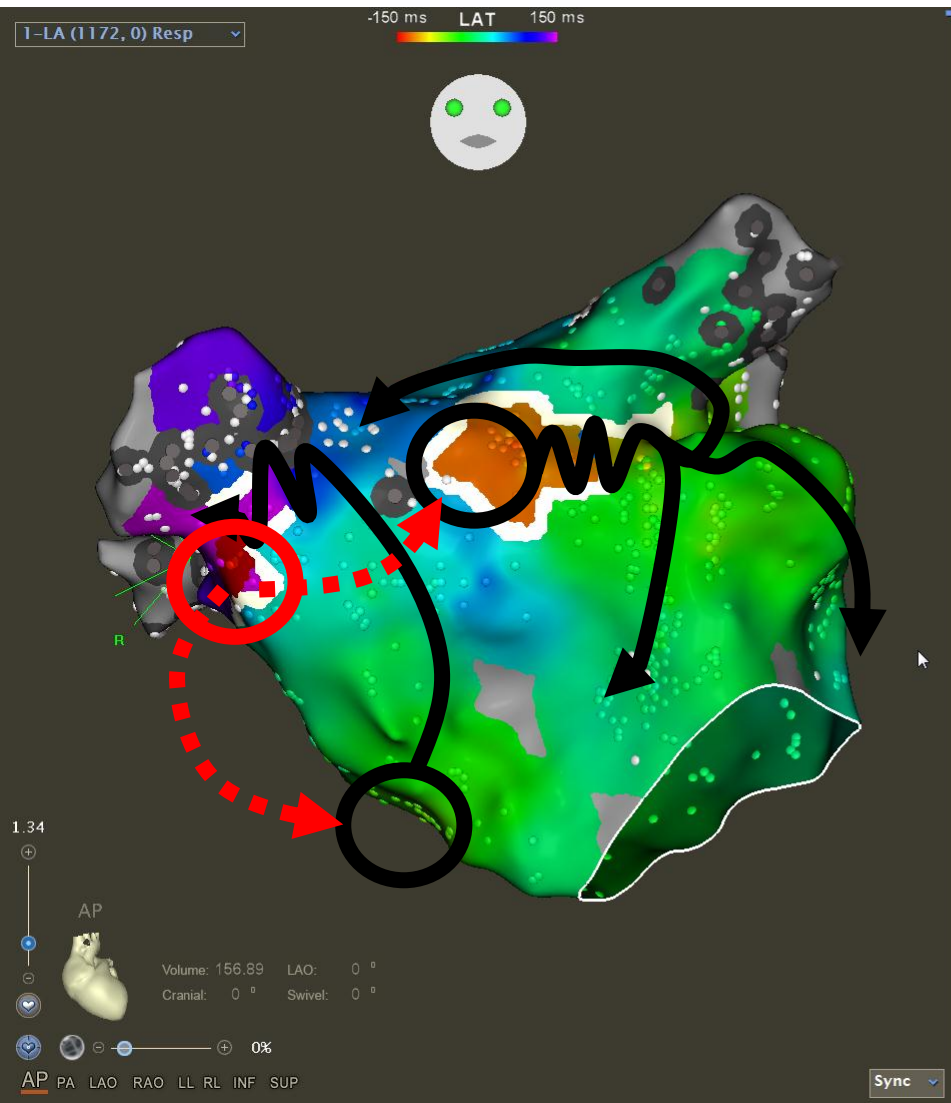
Tachy 1 – Cycle 305ms



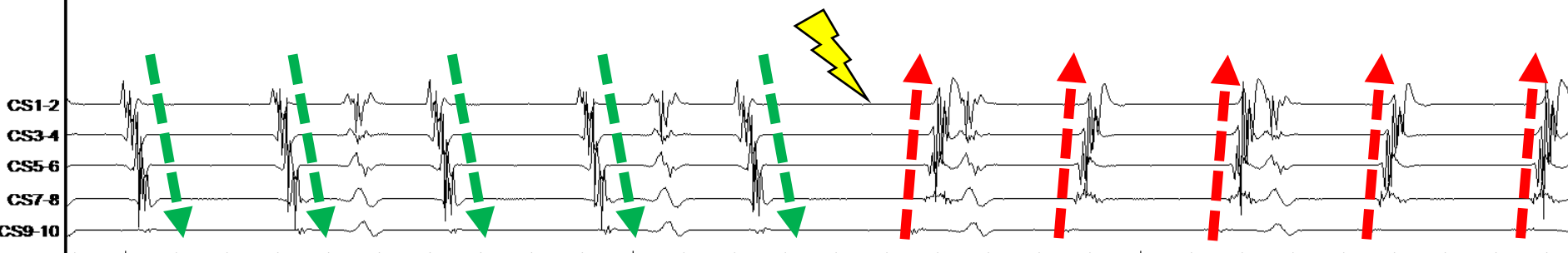
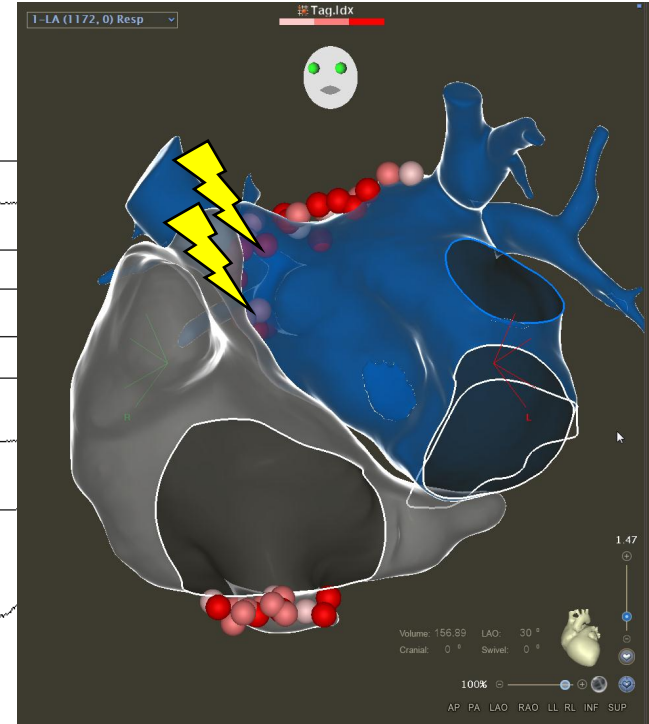
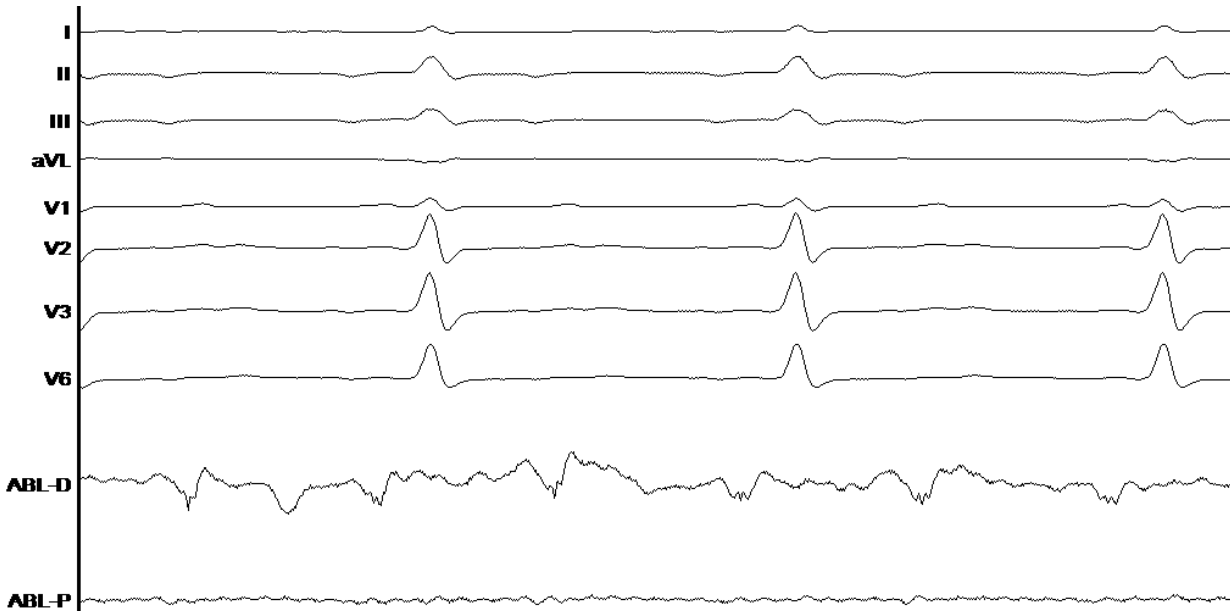
Tachy 1 – Flutter gauche



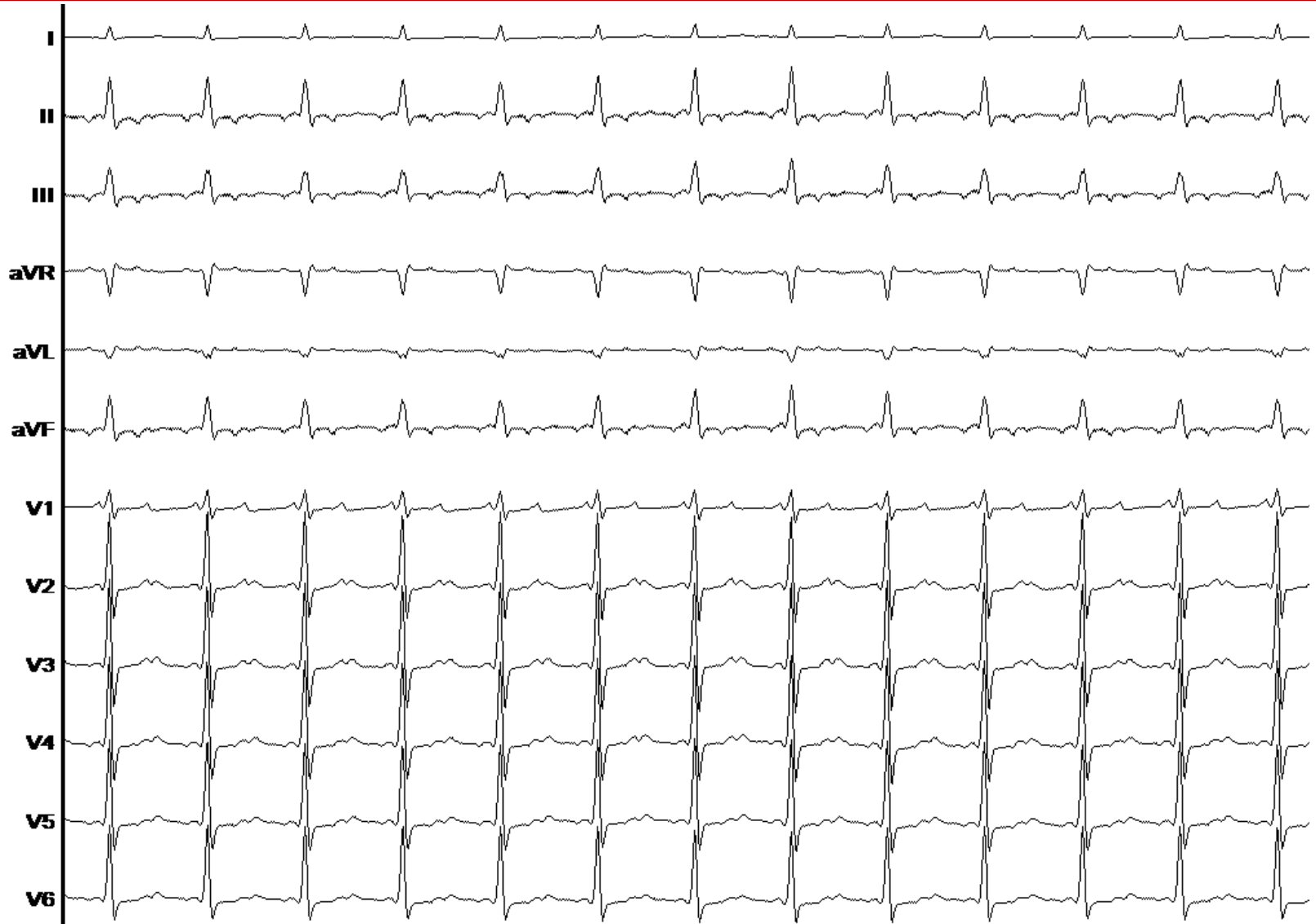
Tachy 1 – Flutter gauche



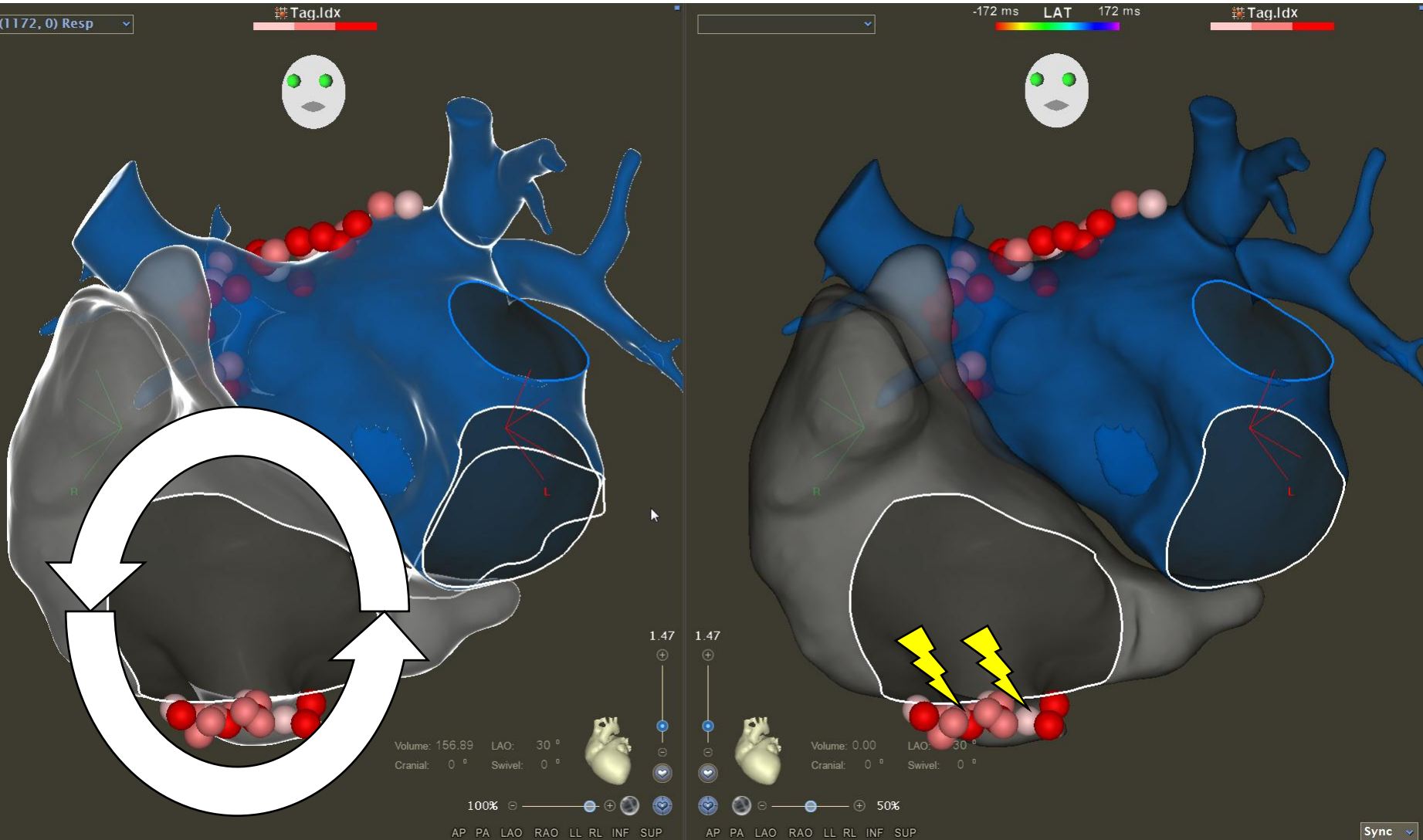
Isolation VPSD



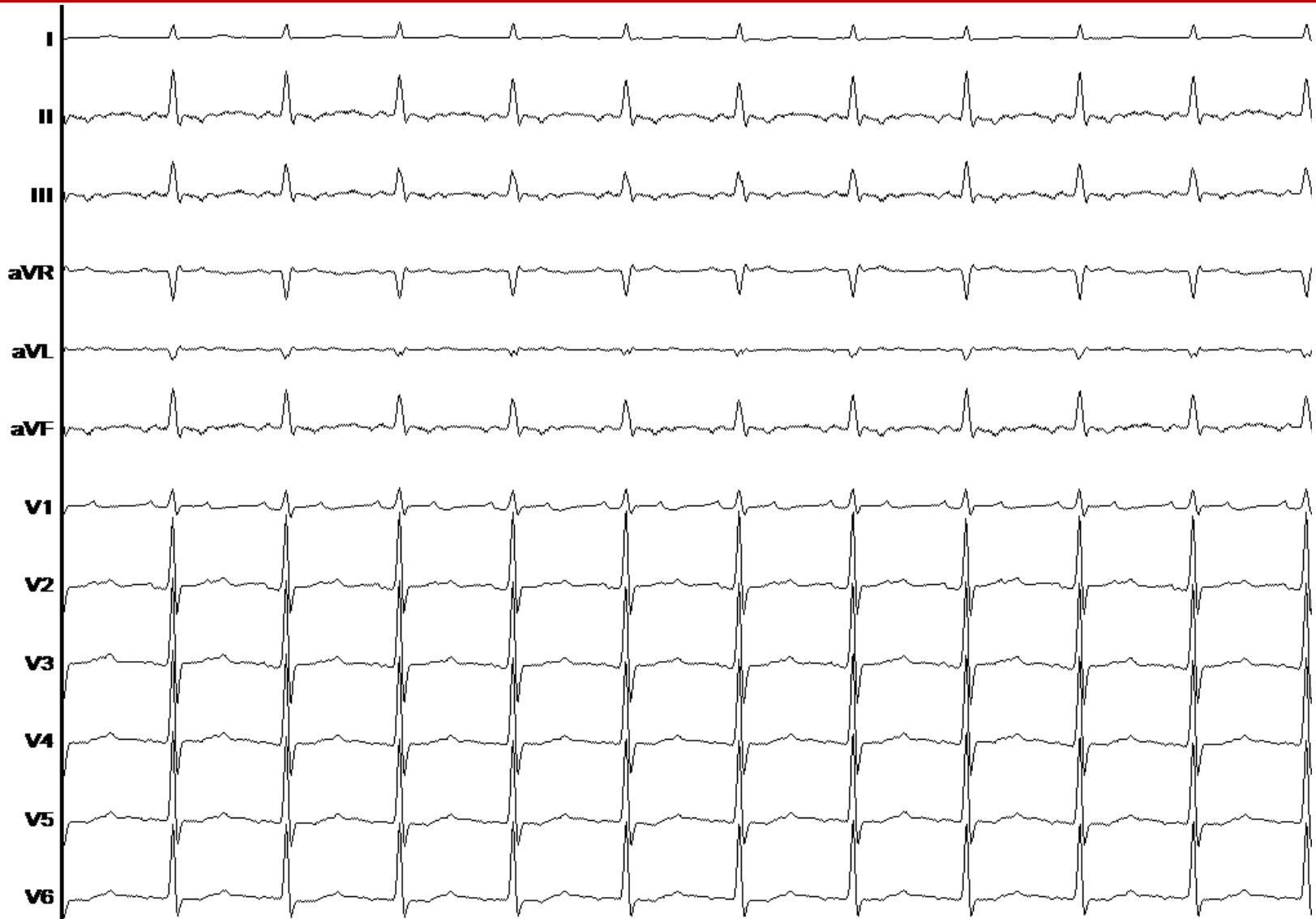
Tachy 2 – Cycle 305ms



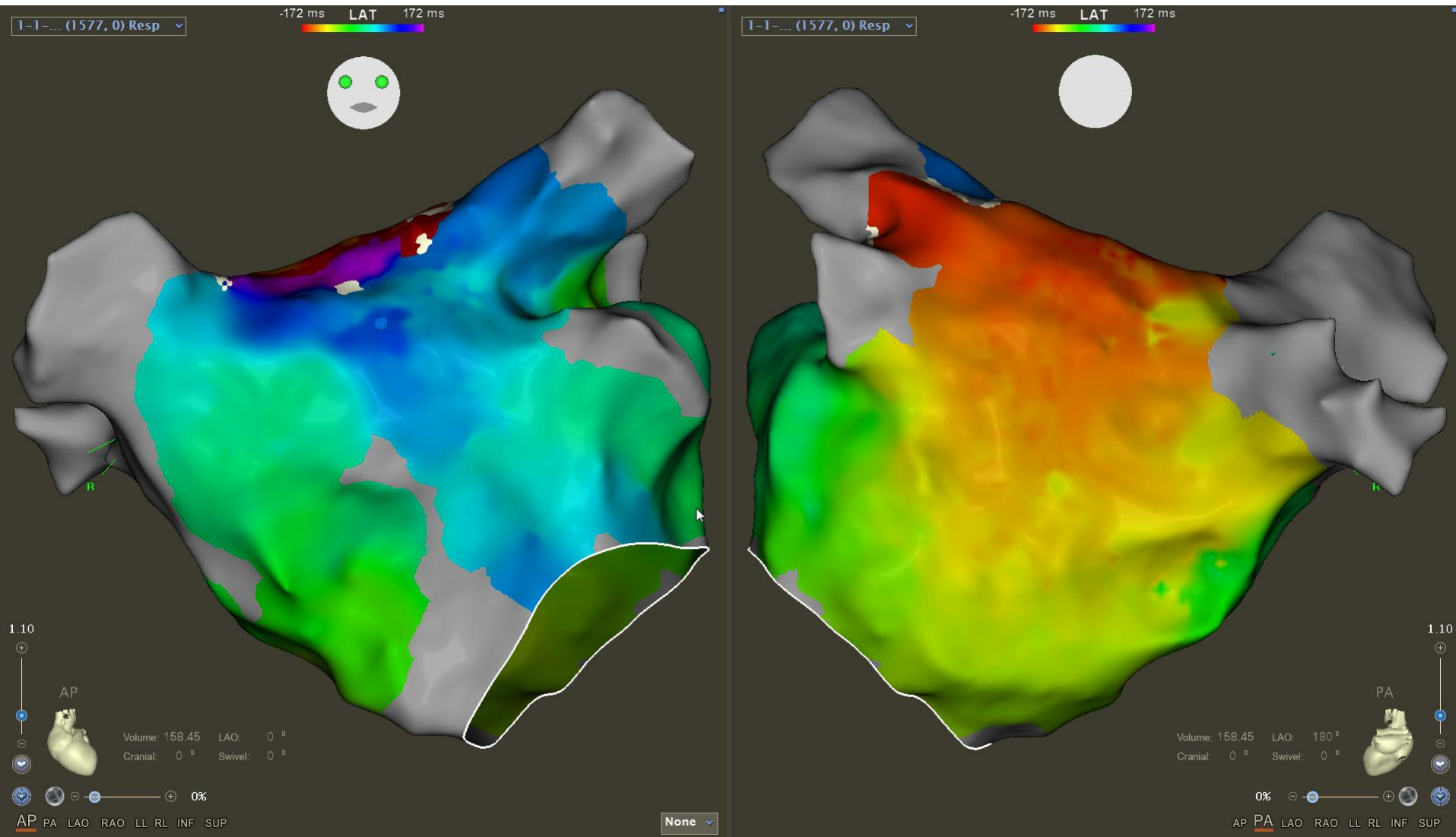
Tachy 2 – Flutter Commun



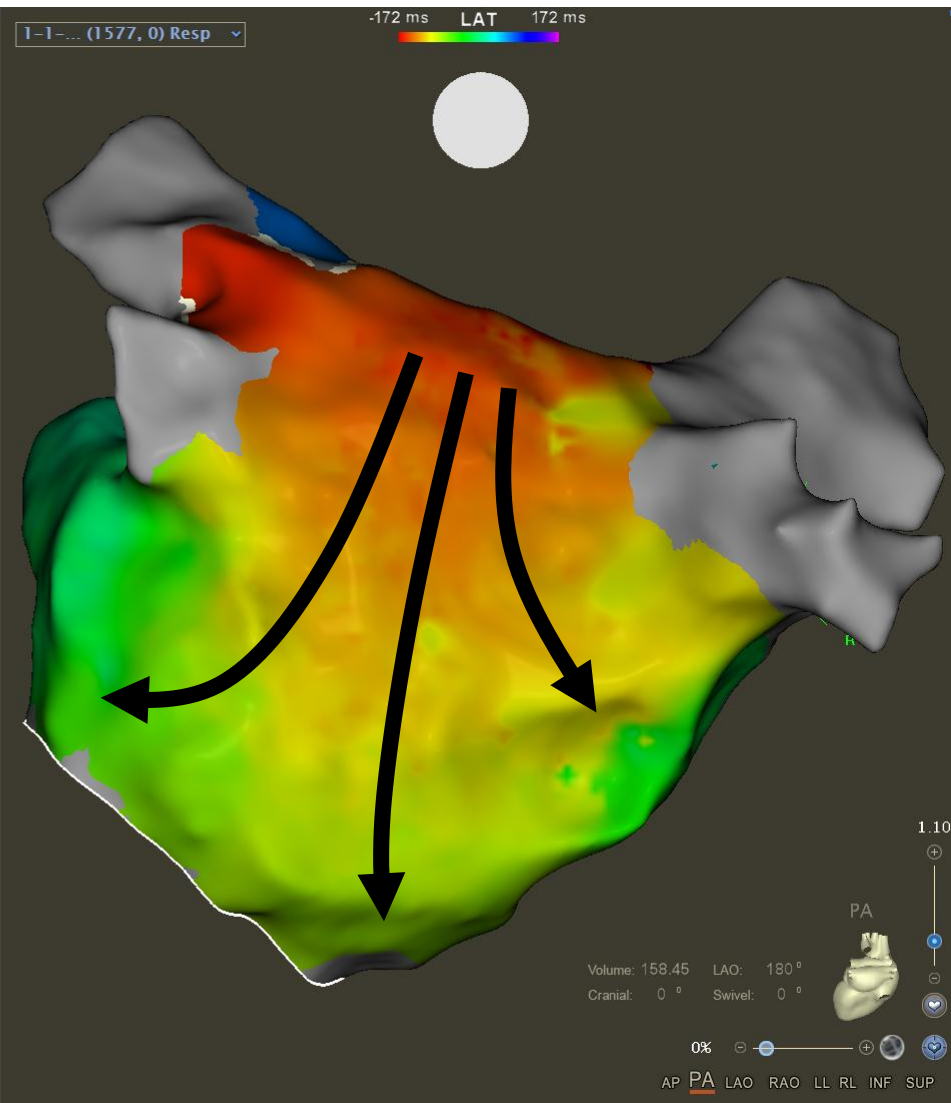
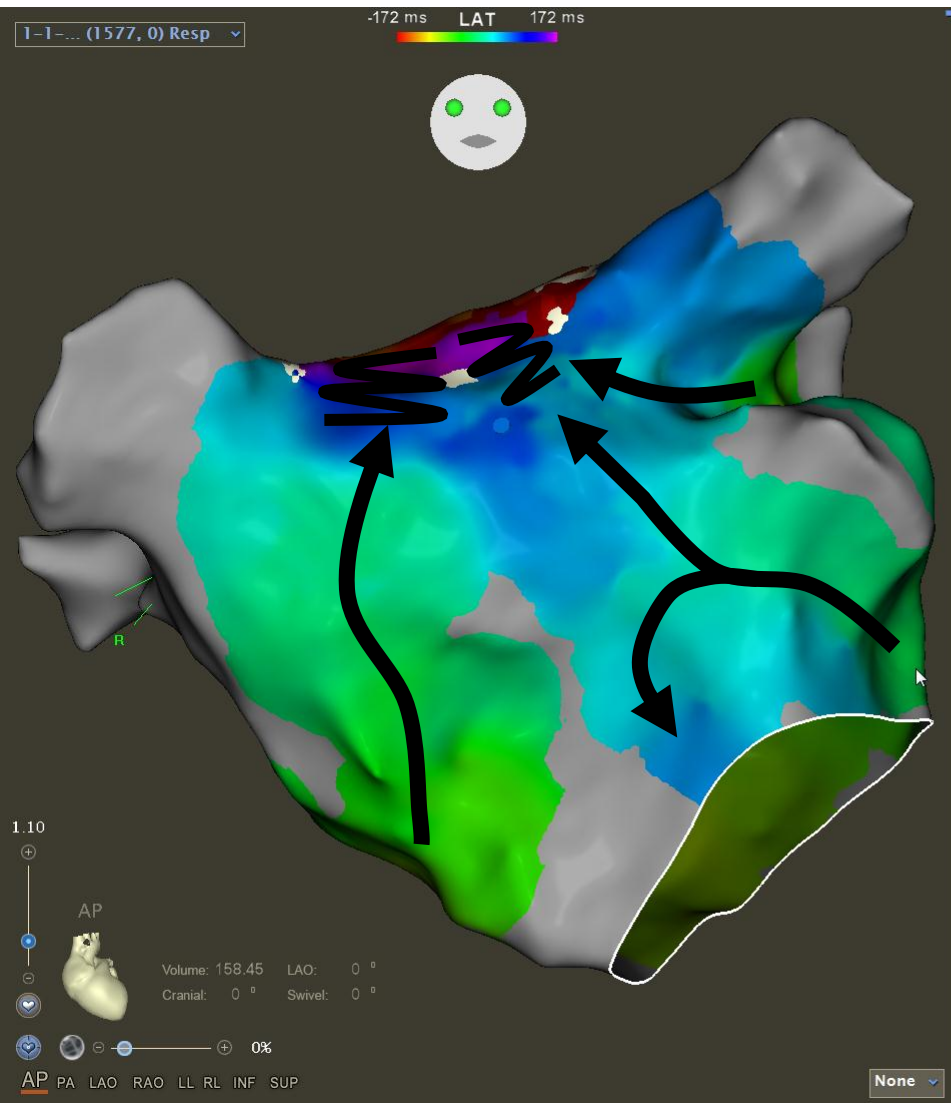
Tachy 3 – Cycle 350ms



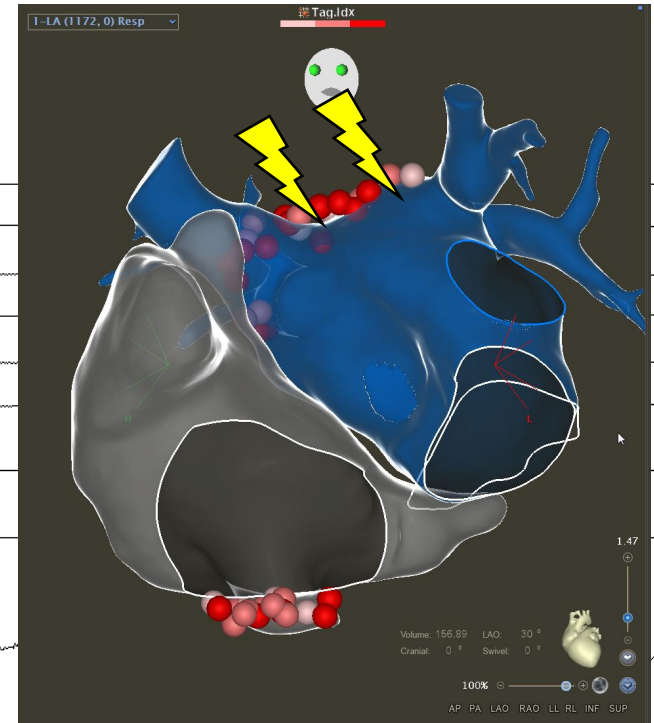
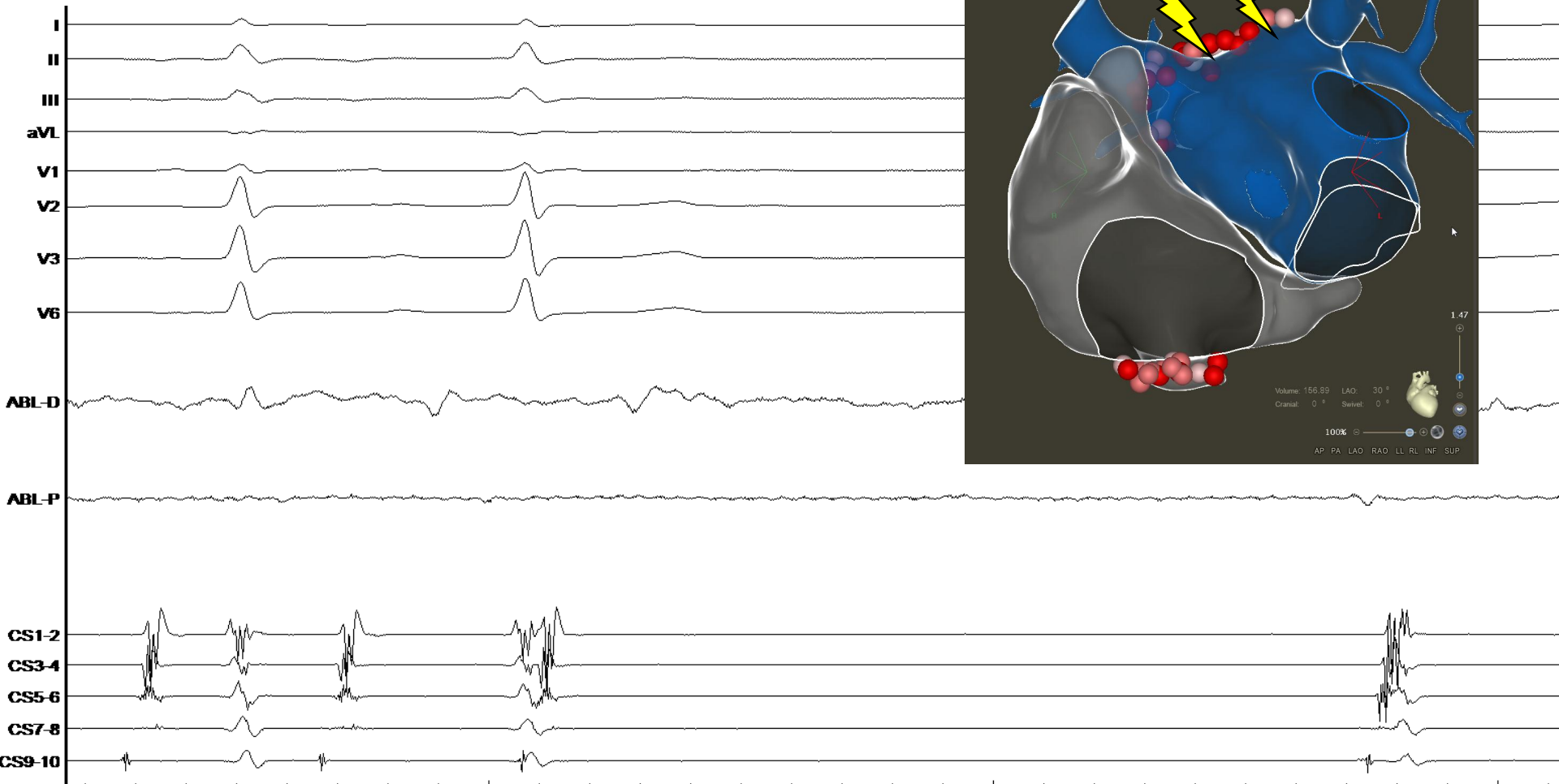
Tachy 3 – Flutter du toit



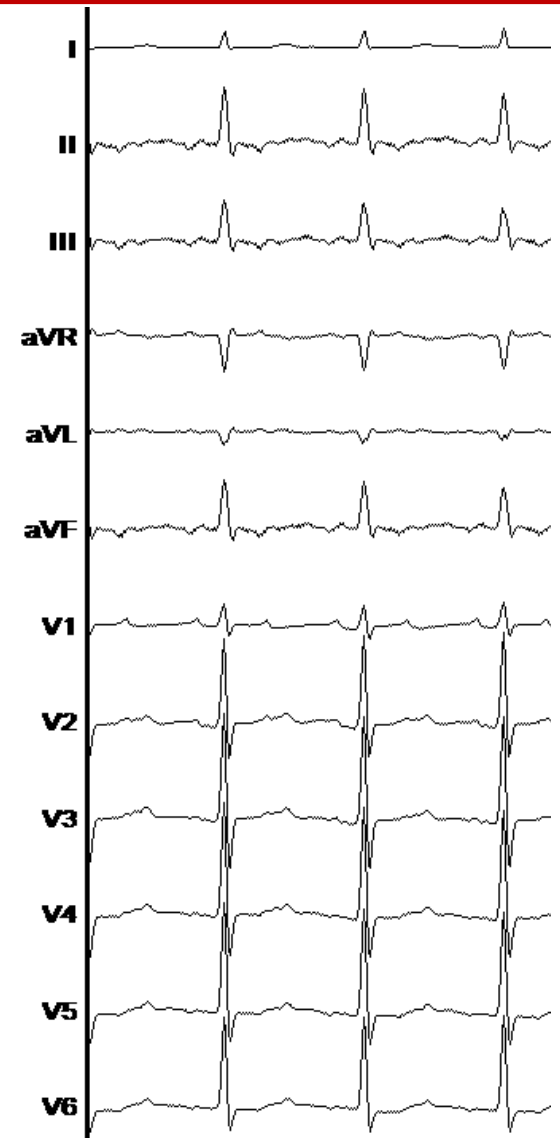
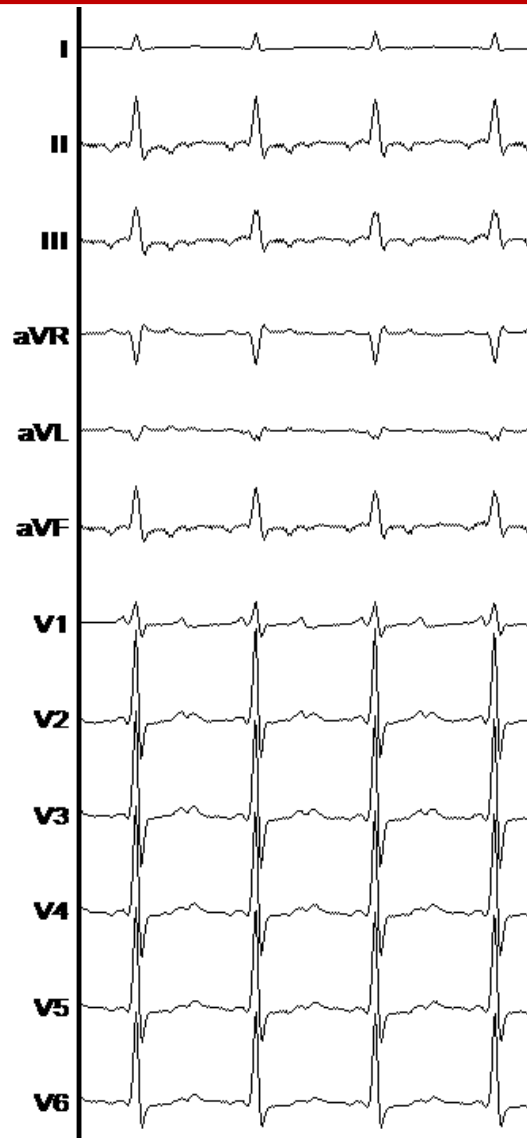
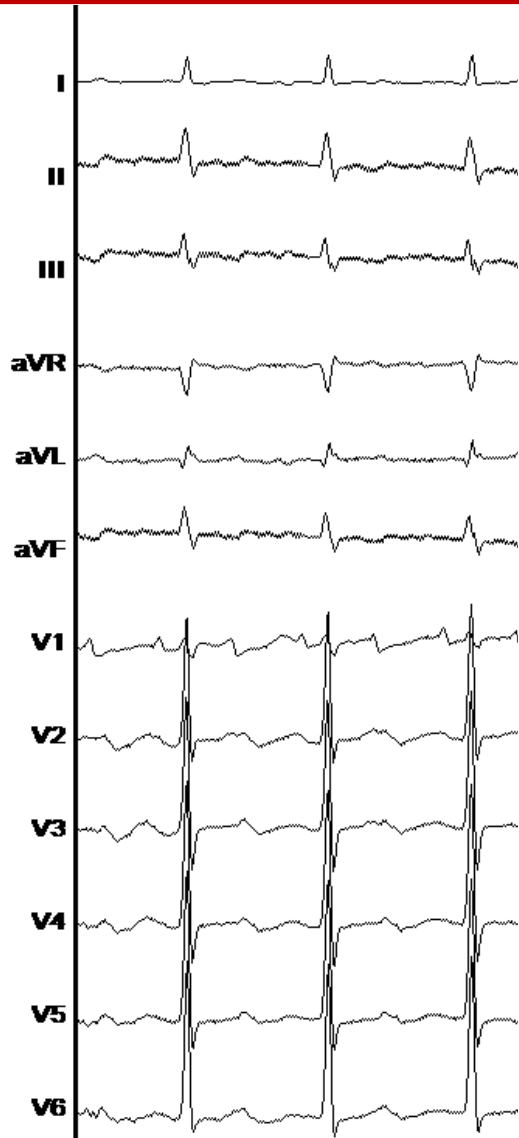
Tachy 3 – Flutter du toit



Ligne du toit – retour sinusal



Tachy 1 – Tachy 2 – Tachy 3



Résumé

- Ablation :
 - 14 min de RF
 - 32 kJ de RF
- Matériel :
 - Pentaray Orange (Biosense)
 - Decanav Orange (Biosense)
 - STSF Noire (Biosense)

