



Ablation TV endo et epi

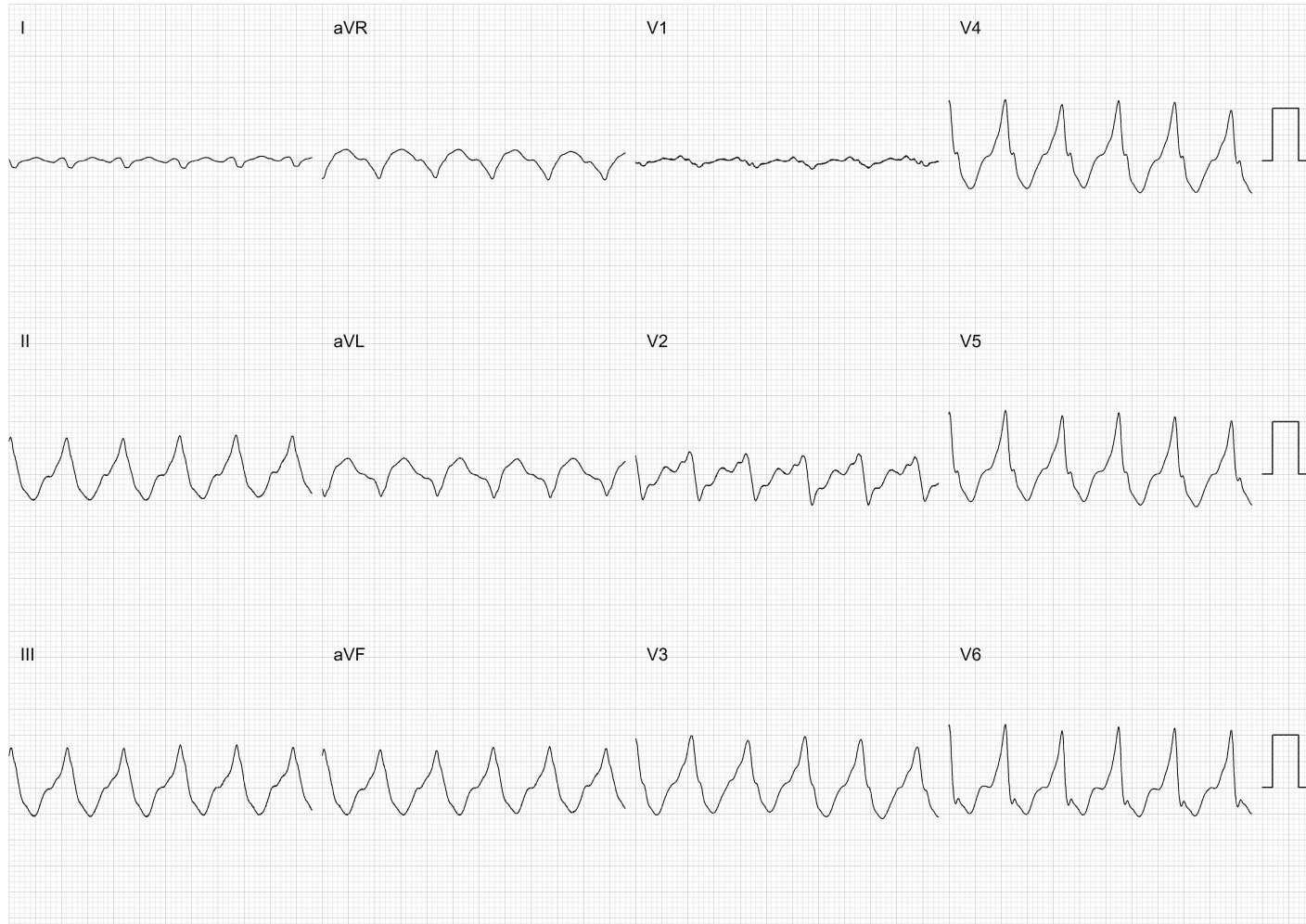Alexis Durand-Dubief

10 mars 2020

Historique patient

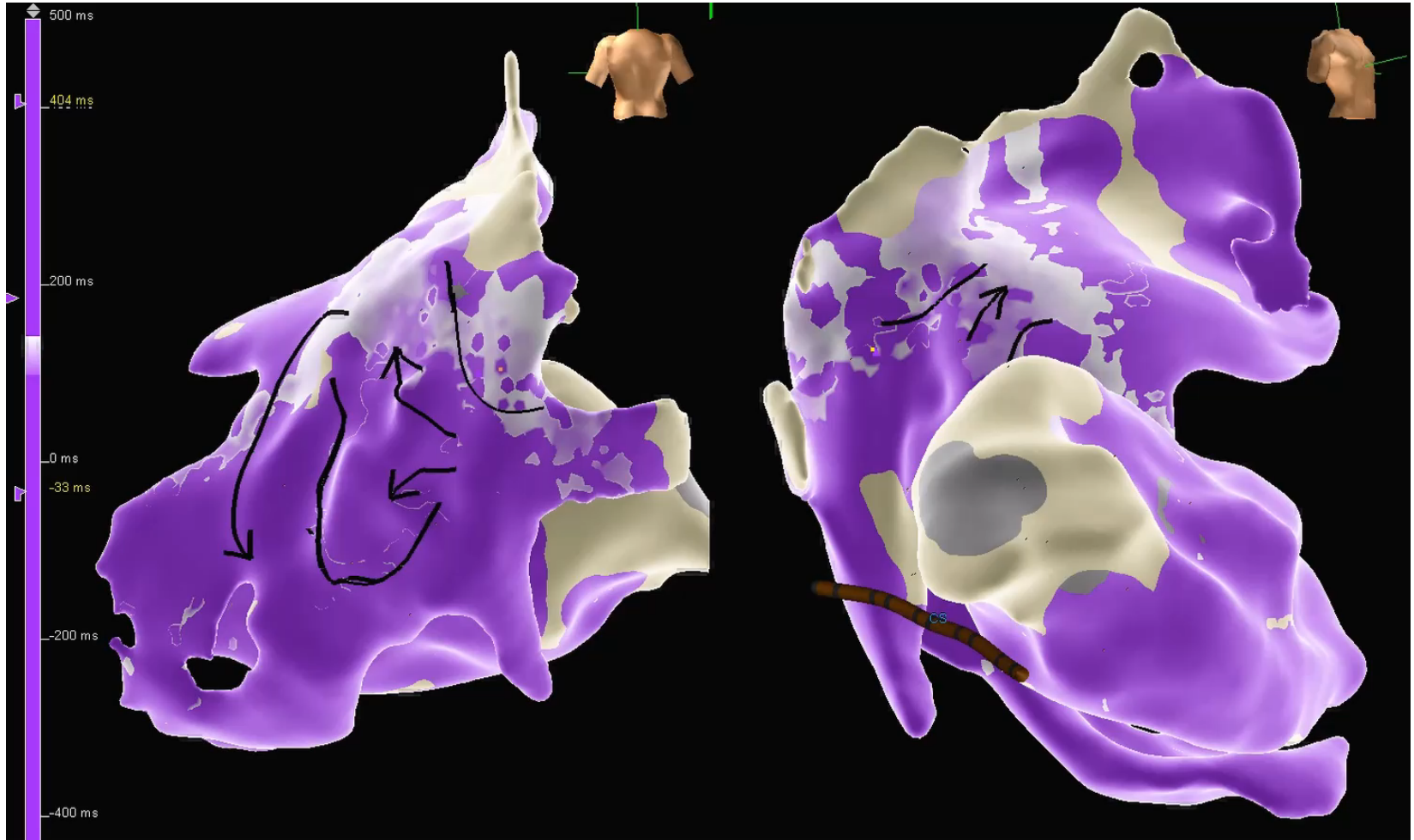
- ATCD Première ablation TV en endo

ECG de la TV

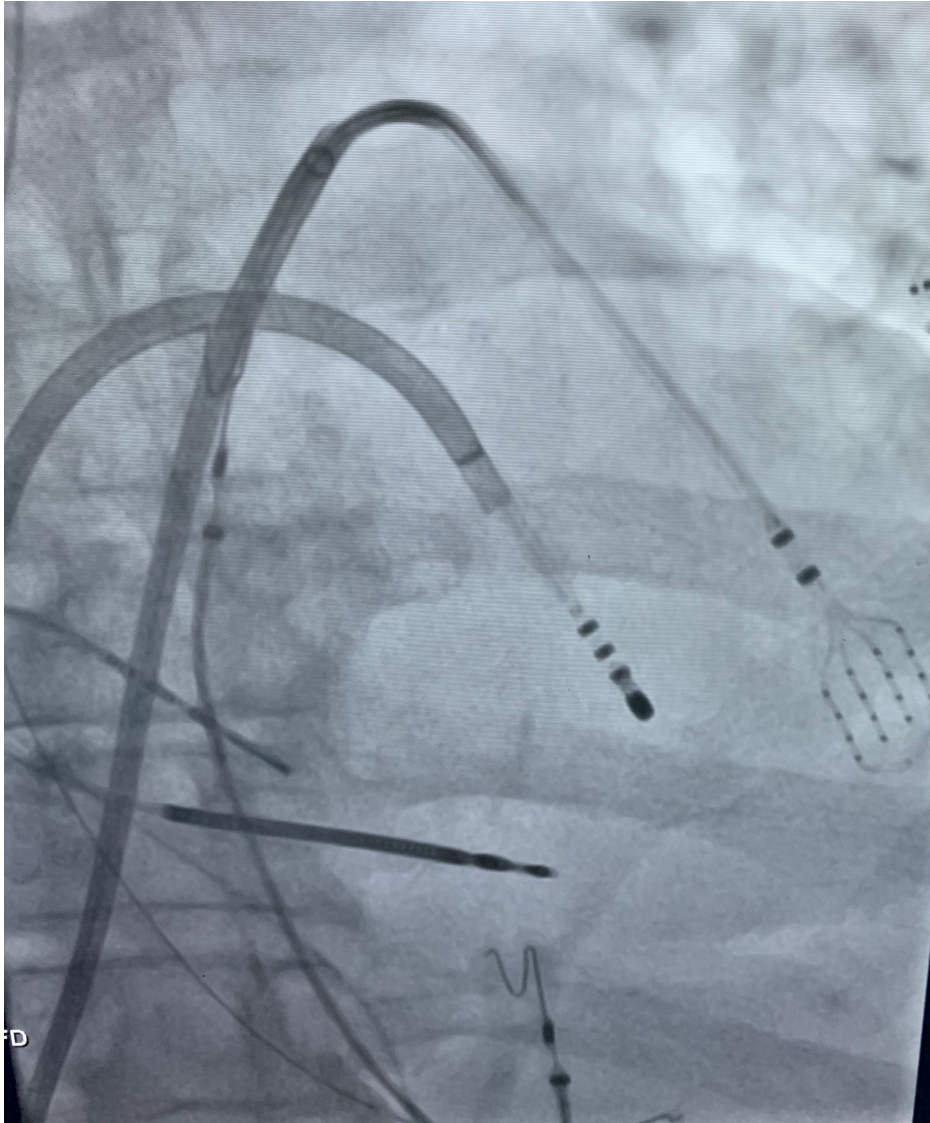


25 mm/s 10 mm/mV Low cutoff: 0.1 Hz, High cutoff: 50 Hz, Notch Filter On, (Low Cutoff of 0.05 Hz recommended for diagnostic ECG)

Activation endo et epi

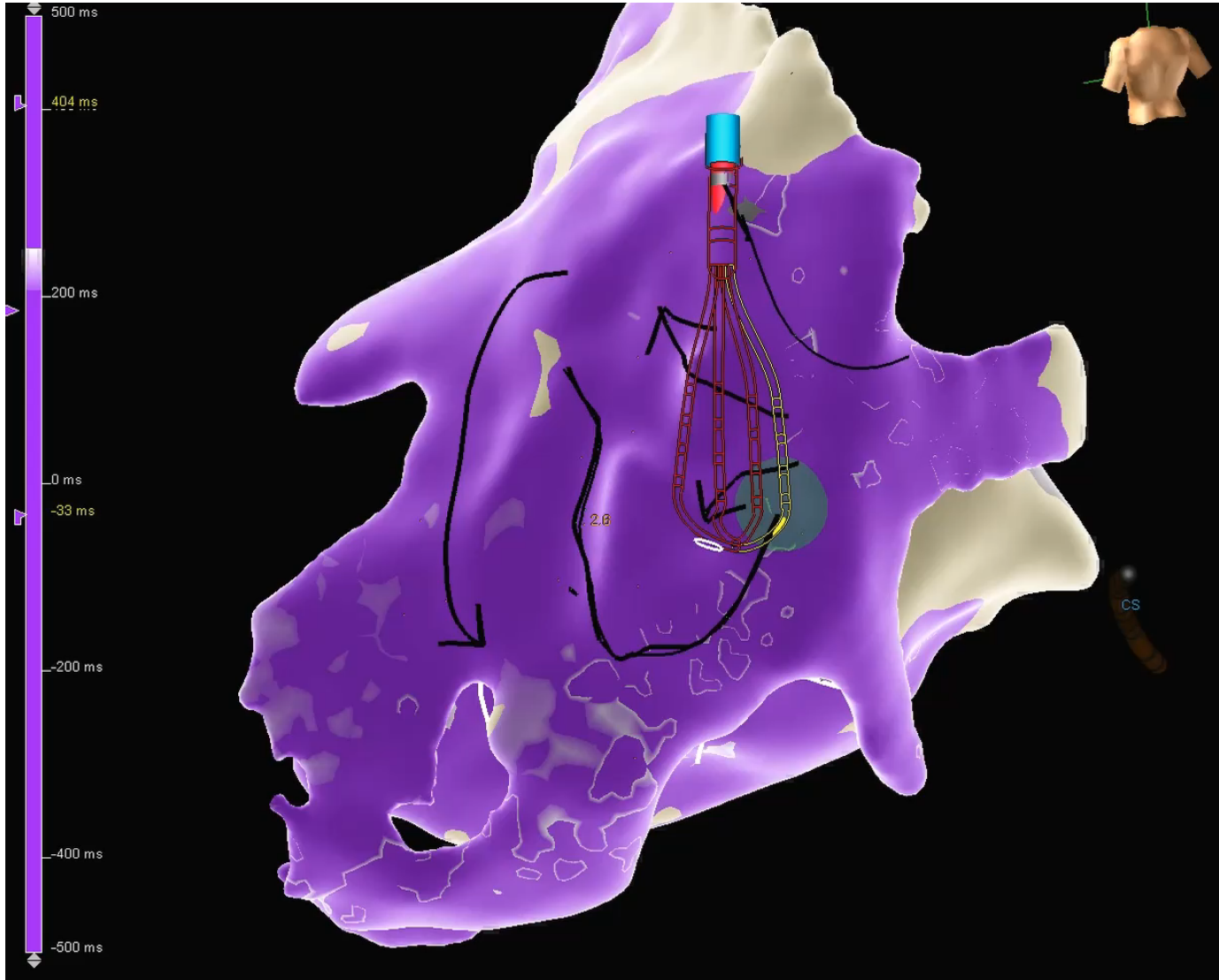


Agilis endo et epi

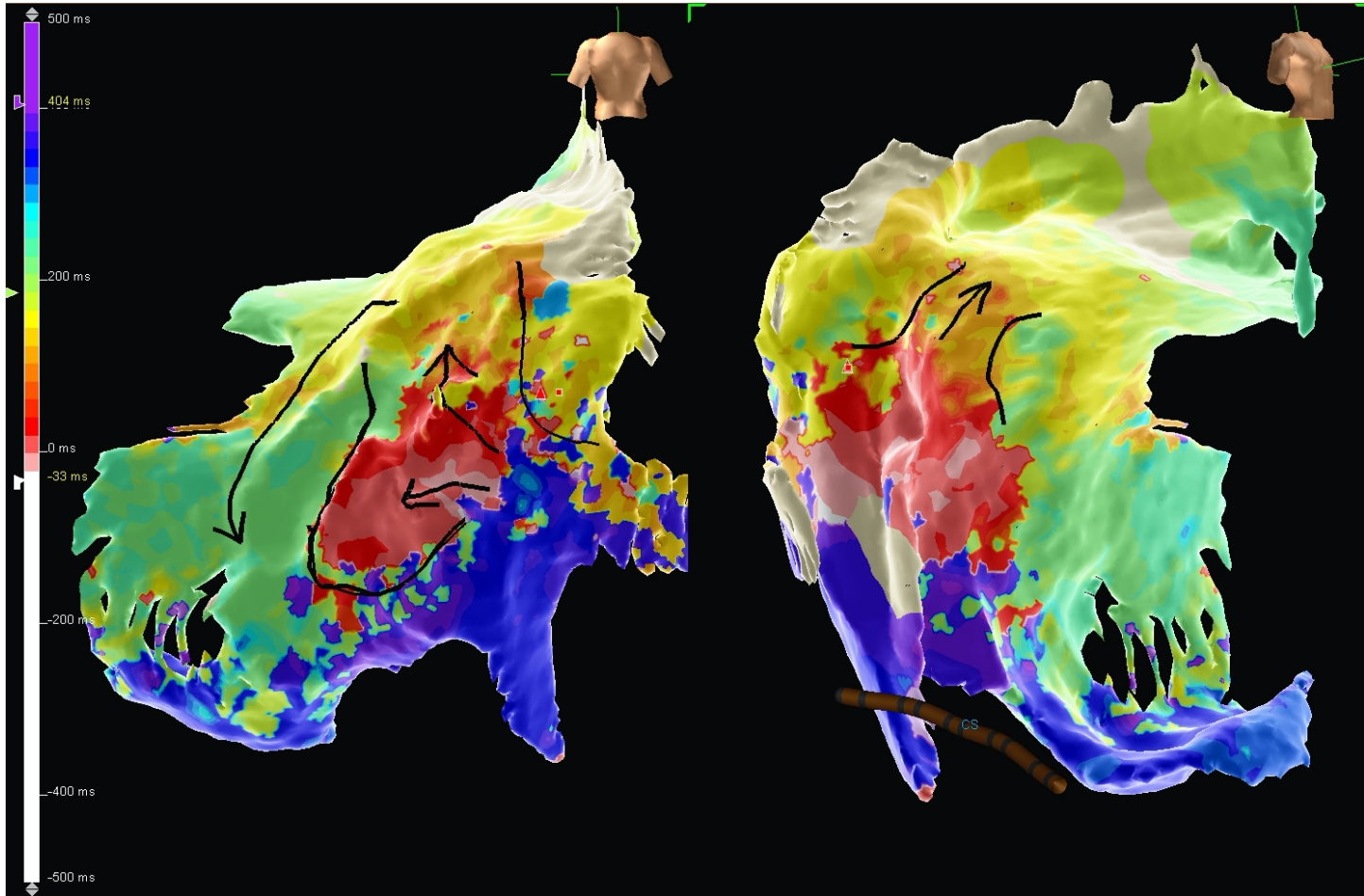


HD Grid en epi, ,Tacticath SE en endo

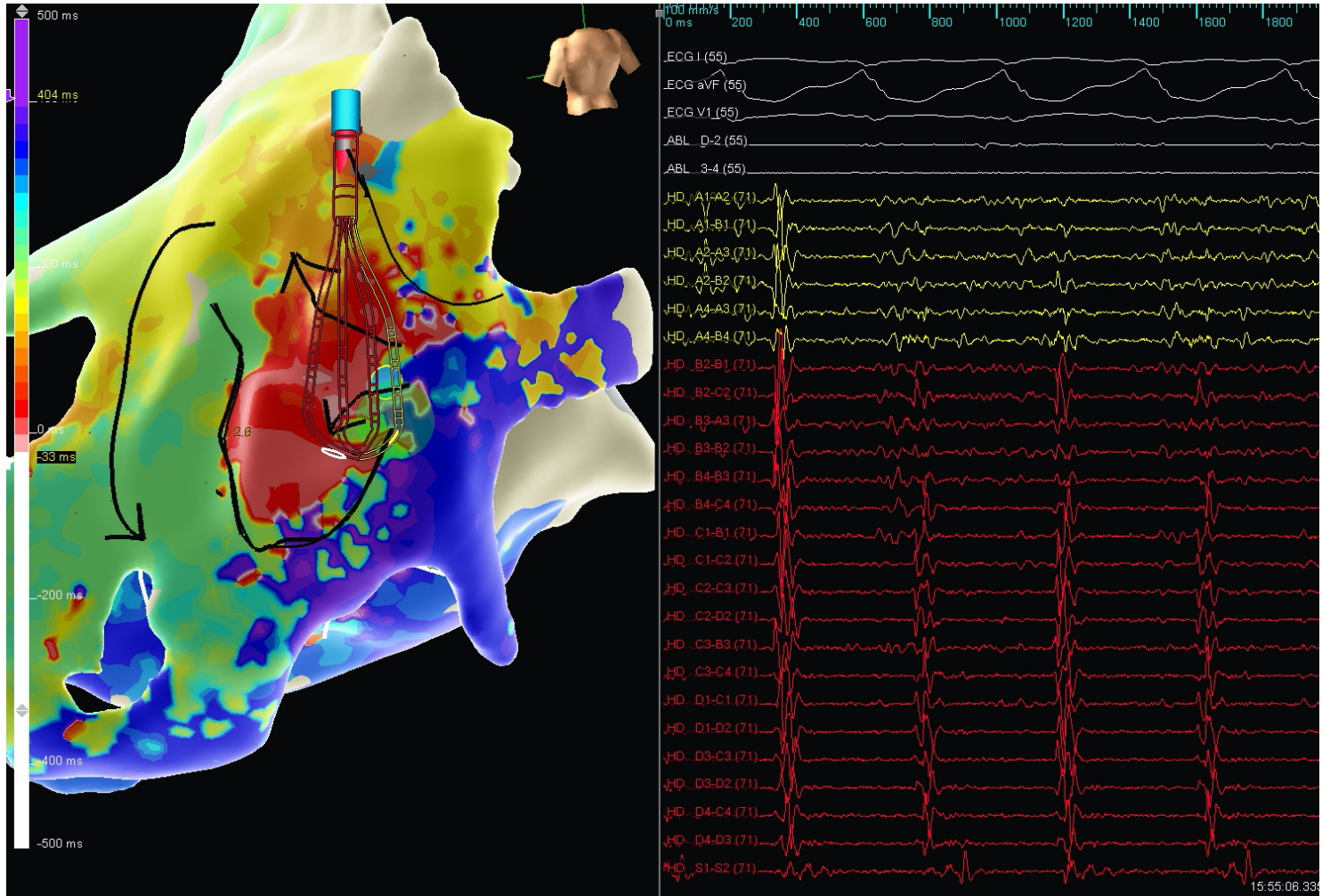
Vidéo activation en epi



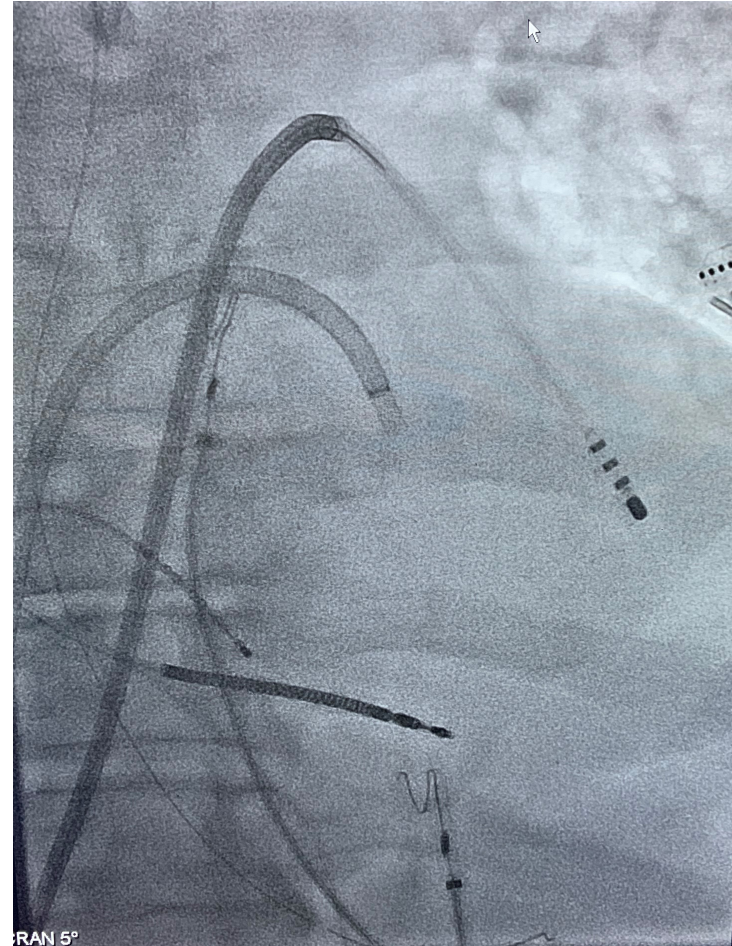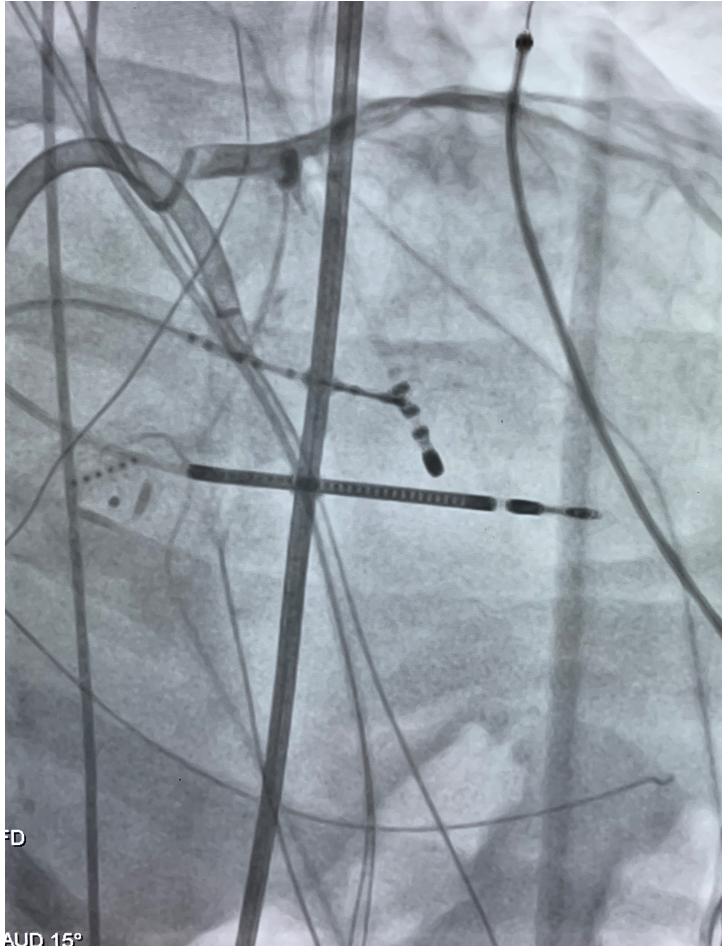
Activation EPI vue interne et externe



Signaux en epi



Injection coronaires avant tirs



Ablation endo et epi

